

Therapeutic Advances in Gastroenterology

<http://tag.sagepub.com>

Effective treatment of chronic radiation proctitis using radiofrequency ablation

Chao Zhou, Desmond C. Adler, Laren Becker, Yu Chen, Tsung-Han Tsai, Marisa Figueiredo, Joseph M. Schmitt, James G. Fujimoto and Hiroshi Mashimo

Therapeutic Advances in Gastroenterology 2009; 2; 149

DOI: 10.1177/1756283X08103341

The online version of this article can be found at:
<http://tag.sagepub.com/cgi/content/abstract/2/3/149>

Published by:



<http://www.sagepublications.com>

Additional services and information for *Therapeutic Advances in Gastroenterology* can be found at:

Email Alerts: <http://tag.sagepub.com/cgi/alerts>

Subscriptions: <http://tag.sagepub.com/subscriptions>

Reprints: <http://www.sagepub.com/journalsReprints.nav>

Permissions: <http://www.sagepub.co.uk/journalsPermissions.nav>

Citations <http://tag.sagepub.com/cgi/content/refs/2/3/149>

Effective treatment of chronic radiation proctitis using radiofrequency ablation

Chao Zhou, Desmond C. Adler, Laren Becker, Yu Chen, Tsung-Han Tsai, Marisa Figueiredo, Joseph M. Schmitt, James G. Fujimoto and Hiroshi Mashimo

Therapeutic Advances in Gastroenterology

(2009) 2(3) 149–156

DOI: 10.1177/
1756283X08103341

© The Author(s), 2009.

Reprints and permissions:
[http://www.sagepub.co.uk/
journalsPermissions.nav](http://www.sagepub.co.uk/journalsPermissions.nav)

Abstract: Endoscopic argon plasma coagulation and bipolar electrocautery are currently preferred treatments for chronic radiation proctitis, but ulcerations and strictures frequently occur. Radiofrequency ablation (RFA) has been successful for mucosal ablation in the esophagus. Here we report the efficacy of RFA with the BarRx Halo⁹⁰ system in three patients with bleeding from chronic radiation proctitis. In all cases, the procedure was well tolerated and hemostasis was achieved after 1 or 2 RFA sessions. Re-epithelialization of squamous mucosa was observed over areas of prior hemorrhage. No stricturing or ulceration was seen on follow-up up to 19 months after RFA treatment. Real-time endoscopic optical coherence tomography (EOCT) visualized epithelialization and subsurface tissue microvasculature pre- and post-treatment, demonstrating its potential for follow-up assessment of endoscopic therapies.

Keywords: endoscopic optical coherence tomography (EOCT), lower gastrointestinal bleeding, chronic radiation proctitis, radiofrequency ablation (RFA), endoscopic therapy

Introduction

Chronic radiation proctitis is a long-term complication of radiotherapy for malignancies of the pelvis, particularly prostate and cervical cancer, occurring in 5–7.5% of patients receiving pelvic irradiation [Donaldson, 1994]. Radiation causes microvascular injury to the mucosa, resulting in ischemia, fibrosis and ultimately development of neovascular lesions [Haboubi *et al.* 1988]. Symptoms from chronic radiation proctitis include hematochezia, diarrhea, mucus discharge, tenesmus, urgency, rectal pain and fecal incontinence. While the disease may resolve spontaneously, in severe cases persistent bleeding can cause iron deficiency, anemia, and the need for blood transfusions [Gilinsky *et al.* 1983].

Effective therapy for chronic radiation proctitis has been limited. Medical therapies including topical sucralfate [Kochhar *et al.* 1991], 5-aminosalicylic acid enemas [Baum *et al.* 1989], short-chain fatty acids [Talley *et al.* 1997], vitamin E [Kennedy *et al.* 2001], and topical application of formalin [De Parades *et al.* 2005; Counter *et al.*

1999] have been largely disappointing. Surgical management carries significant morbidity and mortality risks [Lucarotti *et al.* 1991]. Endoscopic therapy is currently the preferred modality for treating this disease. Options include heater and bipolar probes [Jensen *et al.* 1997; Maunoury *et al.* 1991], neodymium/yttrium aluminum garnet (Nd:YAG) lasers [Ventrucci *et al.* 2001; Barbatzas *et al.* 1996; Viggiano *et al.* 1993], potassium titanyl phosphate (KTP) lasers [Taylor *et al.* 1993], epinephrine or sclerosant injections [Bloomfield *et al.* 2001; Ramirez *et al.* 1996], argon lasers [Taylor *et al.* 1993], and most recently, argon plasma coagulation (APC) [Sebastian *et al.* 2004; Rotondano *et al.* 2003; Villavicencio *et al.* 2002; Taieb *et al.* 2001; Tjandra and Sengupta, 2001; Kaassis *et al.* 2000; Fantin *et al.* 1999]. However, these methods may be complicated by development of rectal pain, diarrhea, tenesmus, ulcers, fistula, rectal stenosis and anal strictures [Rotondano *et al.* 2003; Villavicencio *et al.* 2002; Taieb *et al.* 2001; Taylor *et al.* 2000]. These complications are likely related to the high variability

Correspondence to:

Hiroshi Mashimo
VA Boston Healthcare
System and Harvard
Medical School, MA, USA
[hmashimo@hms.
harvard.edu](mailto:hmashimo@hms.harvard.edu)

Chao Zhou
Desmond C. Adler
Yu Chen
Tsung-Han Tsai
James G. Fujimoto
Department of Electrical
Engineering and Computer
Science and Research
Laboratory of Electronics
Massachusetts Institute of
Technology, Cambridge,
MA, USA

Laren Becker
Marisa Figueiredo
VA Boston Healthcare
System and Harvard
Medical School, MA, USA

Joseph M. Schmitt
LightLab Imaging Inc.,
Westford, MA, USA

in depth of burn achieved by these different modalities. Radiofrequency ablation (RFA) with the BarRx Halo⁹⁰ system has achieved superficial and broad fields of ablation in the esophagus [Sharma *et al.* 2008, 2007; Mashimo *et al.* 2007; Hubbard and Velanovich 2007; Dunkin *et al.* 2006], suggesting that similar benefits could be derived in the colon and rectum. In this report, RFA with the Halo⁹⁰ system was used to treat three patients with lower gastrointestinal bleeding from chronic radiation proctitis, including two who failed conventional therapy.

Patients and methods

Three male patients at the VA Boston Healthcare System (VABHS) with lower gastrointestinal bleeding from endoscopically confirmed chronic radiation proctitis were selected for this case report. After standard polyethylene glycol colonic lavage, RFA was performed in the outpatient endoscopy unit using the Halo⁹⁰ system (BarRx Medical Inc. Sunnyvale, CA). A single use Halo⁹⁰ electrode catheter was fit on the distal end of a standard flexible endoscope. Three-hundred watts of energy per application at 10 J/cm² was delivered to areas of bleeding at the distal rectum. This dosage has been demonstrated to be effective in treating Barrett's esophagus without generating submucosal injury [Dunkin *et al.* 2006; Ganz *et al.* 2004]. White light video endoscopy and narrow band imaging (NBI) using the Evis Extra II high definition system (Olympus America, Center Valley, PA), and endoscopic optical coherence tomography (EOCT) [Tearney *et al.* 1997] was performed pretreatment and at follow-up endoscopies. Two different EOCT systems, one standard speed [Chen *et al.* 2008] and one high-speed [Adler *et al.* 2009; Adler *et al.* 2007], were employed to obtain cross-sectional images of colon architectural morphology. The high-speed system [Adler *et al.* 2007] was available for some patients, and enabled EOCT imaging over larger fields of view with higher frame rates. Imaging was performed by inserting a thin fiber-optic imaging probe down the working channel of the video endoscope.

The EOCT imaging protocol was approved by the Internal Review Boards at VABHS and the Harvard Medical School, and by the Committee on the Use of Humans as Experimental Subjects at MIT. Informed consent was obtained for each EOCT imaging session.

Results

Case 1

A 68-year-old man with a history of prostate cancer status post prostatectomy and radiation therapy (total dose 70.2 Gy) 3 years ago presented with rectal bleeding from chronic radiation proctitis. The patient underwent flexible sigmoidoscopy with APC, but returned to ER 3 days later with continuous and worsened bleeding. Repeat flexible sigmoidoscopy revealed persistent bleeding from multiple ulcerations at sites of prior APC (Figures 1a and 1b). On EOCT, ectatic blood vessels measuring approximately 50 μ m in diameter were identified as hyperscattering structures that cast a hypointense shadow underneath. Circumferential RFA was performed over areas of bleeding just proximal to the dentate line in the distal rectum with successful hemostasis. Flexible sigmoidoscopy was performed 2 months later and squamous epithelium was found at the site of prior RFA, extending approximately 1 cm from the dentate line (Figures 1c and 1d). A second session of RFA was performed to ablate remaining ectatic vessels. The patient did not experience rebleeding afterward. Follow-up endoscopies with EOCT were performed at 8, 12 and 14 months. The neosquamous epithelium was clearly seen 14 months after the initial RFA treatment (Figures 1e and 1f). The RFA procedures were tolerated well and there have been no complications including strictures or ulcerations in the 17 months since the last treatment.

Case 2

A 76-year-old man with a history of prostate cancer status post radiation therapy (total dose 77.4 Gy) 2 years ago presented with rectal bleeding and underwent direct bipolar electrocautery therapy for bleeding ectatic vessels. The patient presented again with rectal bleeding 1 year later and was treated with APC. He noted occasional blood per rectum, approximately once a month. Eight months later, the patient returned with continued oozing of blood from the rectum for 1 week. RFA was performed over areas of bleeding ectatic vessels. The patient was examined with white light video endoscopy pre-RFA treatment, 8 months post-RFA treatment, and 13 months post-RFA treatment. EOCT images were taken pre-RFA treatment and 8 months post-RFA treatment. The patient's tolerance of the procedures was good. Similar to the first case, ectatic blood vessels (40–110 μ m in

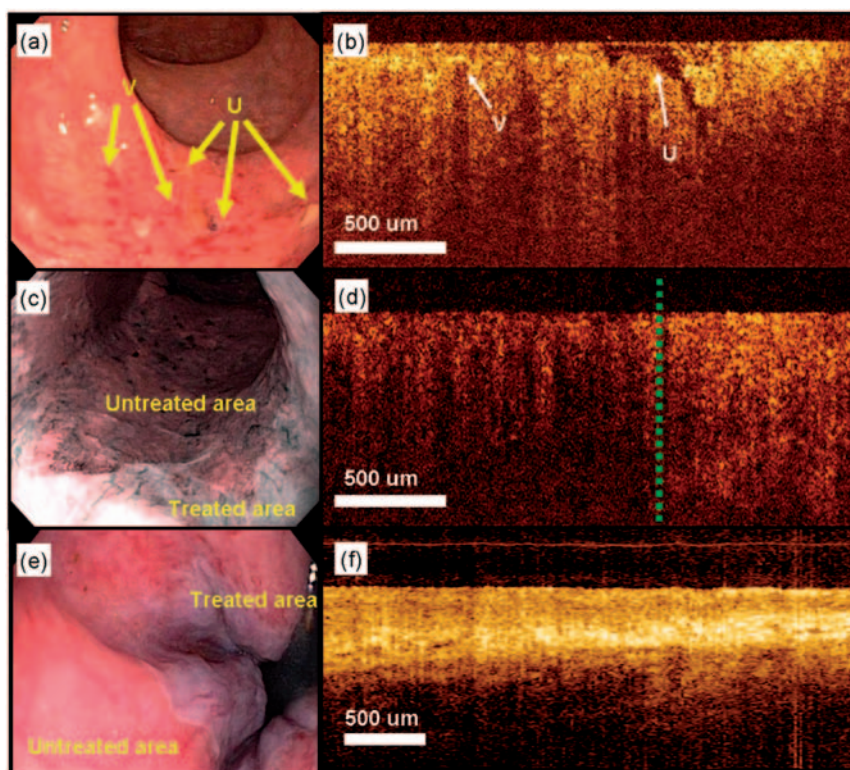


Figure 1. Endoscopic and EOCT images acquired for Case 1 pre-RFA treatment and 2 and 12 months post-RFA treatment. Ectatic vessels (V) due to radiation proctitis and ulcerations (U) due to APC 3 days earlier were observed under (a) endoscopic and (b) EOCT imaging prior to RFA treatment. The slowly oozing ulcerations were revealed after the overlying blood and clots were gently flushed away. Two months after the initial RFA treatment, (c) endoscopic NBI and (d) EOCT demonstrated squamous epithelialization over the treated area (right of the dashed line), while columnar epithelium was observed over the untreated area (left of the dashed line) with EOCT. At 14 months post-RFA treatment, (e) endoscopic and (f) EOCT imaging shows excellent re-epithelialization over the treated area.

diameter) were clearly identified in the EOCT and video endoscopy images prior to the RFA-treatment (Figures 2a and 2b). Images from 8 months post-RFA (Figures 2c and 2d) showed squamous epithelialization over prior hemorrhagic sites with oral marching of the border of the dentate line by about 2 cm, covering former sites of distal ectatic vessels. Similar observations were noted at 13 months post-RFA treatment. No rebleeding, stricture or ulceration was observed after the RFA treatment.

Case 3

A 72-year-old man with a history of prostate cancer underwent 45 Gy radiation to the pelvis followed by boost brachytherapy seed implant and concomitant hormonal therapy. The patient presented with rectal bleeding 14 months after his last hormonal therapy injection and was diagnosed with chronic radiation proctitis.

Ectatic vessels ($\sim 50 \mu\text{m}$ in diameter) were observed under white light video endoscopy and EOCT (Figures 3a and 3b). The patient underwent circumferential RFA treatment over areas of active bleeding in the most caudal 2 cm span above the dentate line. Good stasis of bleeding was achieved immediately. Six months later, the patient returned with a small area containing ectatic vessels ($\sim 40 \mu\text{m}$ in diameter) oral to the treatment site. The remainder of the rectum was well epithelialized (Figures 3c and 3d). The area of bleeding was treated with focal application of RFA (300 W and 10 J/cm^2), resulting in stasis of bleed. No subsequent bleeding was reported following this treatment. Endoscopic imaging at 12 months post the initial RFA treatment showed excellent re-epithelialization over prior oozing vessels, extending the dentate line by about 1–2 cm oral. The patient's tolerance of the procedures was good.

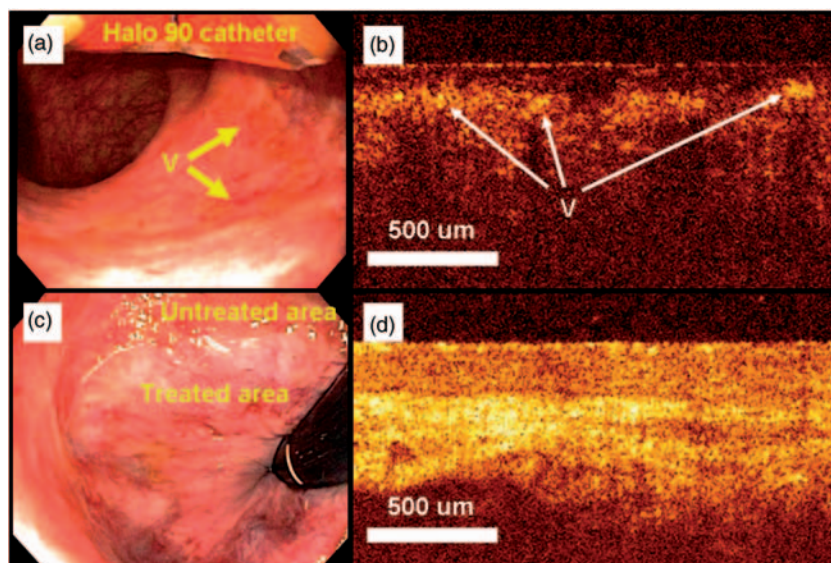


Figure 2. Endoscopic and EOCT images acquired for Case 2 at pre- and 8 months post-RFA treatment. Ectatic vessels (V) were observed under (a) endoscopic examination and (b) EOCT prior to the RFA treatment. Eight months post-RFA treatment, squamous epithelialization over the RFA-treated area was observed with (c) endoscopic and (d) EOCT imaging. The dentate line is estimated to have extended ~2 cm from the anal verge.

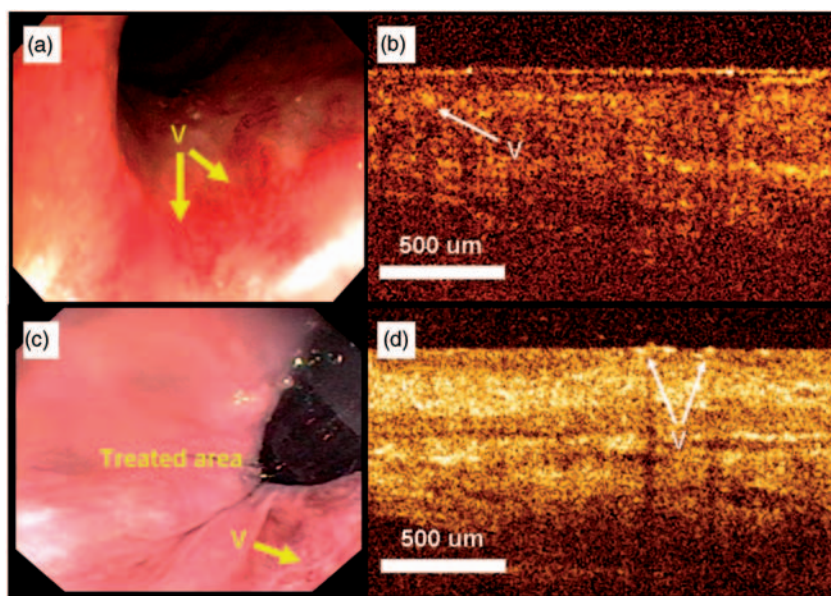


Figure 3. Endoscopic and EOCT images acquired for Case 3 at pre- and 6 months post-RFA treatment. Ectatic vessels (V) were observed under (a) endoscopic examination and (b) EOCT prior to the RFA treatment. Six months post-RFA treatment, ectatic vessels were observed under (c) endoscopic examination and (d) EOCT over a small area oral to the treatment site, while most of the treated rectum was well epithelialized.

Discussion

As demonstrated from the three cases, RFA possesses several benefits compared to other treatments for radiation proctitis. For example, APC

can result in post-treatment ulceration from deeper injury in relatively ischemic mucosa [Rotondano *et al.* 2003; Villavicencio *et al.* 2002; Taieb *et al.* 2001; Taylor *et al.* 2000].

By comparison, the tightly spaced bipolar array of the RFA catheter limited the radiofrequency energy penetration, restricting the RFA treatment to the superficial mucosa, thereby avoiding deep tissue injury. This observation is consistent with previous reports using RFA for the treatment of Barrett's esophagus [Sharma *et al.* 2008, 2007; Dunkin *et al.* 2006; Ganz *et al.* 2004]. Furthermore, squamous re-epithelialization following RFA may play a significant role in the prevention of rebleeding, whereas strictures, ulceration and rebleeding in the formerly inflamed mucosa are commonly noted following conventional endoscopic therapies. The relative lack of stricturing observed following RFA treatments in the upper gastrointestinal tract [Sharma *et al.* 2008; 2007; Smith *et al.* 2007; Ganz *et al.* 2004] was also noted upon follow-up of these patients. Finally, RFA allows broad areas of tissue to be treated simultaneously compared to the point-by-point approach required with heater or bipolar probes [Jensen *et al.* 1997; Maunoury *et al.* 1991], or APC [Kaassis *et al.* 2000; Fantin *et al.* 1999]. However, systematic assessment of any superiority of the RFA method over traditional treatments would require recruitment of a larger number of patients.

Optical coherence tomography (OCT) is an emerging medical imaging technique that is analogous to ultrasound, except that images are generated by measuring echo time delays of light waves instead of sound [Huang *et al.* 1991]. Endoscopic OCT (EOCT), performed with a small diameter fiber-optic imaging probe introduced in the working channel of standard endoscopes, enables two-dimensional (2D) depth-resolved imaging of tissue microstructure over several millimeters with micron-scale resolutions [Tearney *et al.* 1997]. EOCT has been applied for general GI imaging [Bouma *et al.* 2000; Jäcke *et al.* 2000; Sivak *et al.* 2000] and has been intensely studied for the analysis of Barrett's esophagus [Chen *et al.* 2007; Evans *et al.* 2006; Qi *et al.* 2006; Isenberg *et al.* 2005; Poneros *et al.* 2001; Li *et al.* 2000]. In this report, white light video endoscopy combined with NBI and real-time *in vivo* EOCT enabled assessment of treatment efficacy following RFA treatment of chronic radiation proctitis. EOCT can resolve subsurface tissue microstructure in real time without the need for excisional biopsy. This is particularly important for patients with radiation proctitis since biopsy is contraindicated due to the high risk of bleeding. Recent advances in

ultra-high-speed EOCT technology have enabled 3D volumetric imaging over several square centimeters, enabling comprehensive analysis of tissue architectural morphology. Ultrahigh speed technology can also be combined with Doppler OCT [Chen *et al.* 1997a; Chen *et al.* 1997b; Izatt *et al.* 1997], which analyzes the Doppler shift of the backscattered light to detect blood flow. Ectatic vessels could be more clearly distinguished from the surrounding tissue using Doppler OCT. Ectatic sites could be mapped over a large field of view in three dimensions using ultra-high-speed OCT and Doppler detection, which could lead to new analytic methods for evaluating inflammatory pathologies such as radiation proctitis. Accurate quantification of subsurface vessel diameter, vascular density and blood flow rates are therefore possible when Doppler OCT is employed in conjunction with ultra-high-speed OCT.

In addition to the RFA treatment presented in this report, a variety of endoscopic ablative therapies [Fantin *et al.* 1999; Jensen *et al.* 1997; Ramirez *et al.* 1996; Viggiano *et al.* 1993; Taylor *et al.* 1993; Maunoury *et al.* 1991] are currently available to treat lower gastrointestinal bleeding in patients with chronic radiation proctitis. The selection of an optimal treatment may be aided by a detailed microstructural analysis of the lesion *in vivo*. Following endoscopic therapies, pathologic structures may persist or grow underneath neo-epithelialized tissue. These changes can be difficult or impossible to detect using white light video endoscopy. EOCT, on the other hand, can be used to determine the stage or severity of pathology in diseased tissue in order to select an appropriate therapy by providing depth-resolved morphological images. EOCT can also be used to check the treatment site for recurrence or to assess healing following therapies. Therefore, gastroenterologists could benefit from the wide application of EOCT in the future to aid in preinterventional planning and follow-up assessment of endoscopic therapies.

Conclusion

In summary, we have achieved effective control of lower gastrointestinal bleeding in three patients with chronic radiation proctitis using RFA with the BarRx Halo⁹⁰ system. Excellent re-epithelialization and absence of ulcerations or strictures was observed following the

RFA treatment. EOCT, used in conjunction with white light video endoscopy and NBI, was demonstrated to be a uniquely suited imaging modality for assessing treatment by providing real-time subsurface imaging of tissue microstructure *in vivo*.

Authorship

CZ, DCA, YC, JGF and HM have assisted with study design; CZ, DCA, LB, YC, THT, MF and HM have assisted with data collection; CZ, DCA, LB and HM have assisted with data analysis; all the authors have contributed to the manuscript preparation.

Conflict of interest statement

JGF receives royalties from intellectual property owned by the Massachusetts Institute of Technology (MIT) and licensed to LightLab Imaging. JS is an employee of LightLab Imaging. HM, CZ, DCA, LB, YC, THT and MF have no competing financial interests in this work.

Acknowledgement

This work was supported by the NIH grants R01-CA75289-12 (JGF and HM), Air Force Office of Scientific Research contract FA9550-07-1-0014 (JGF) and Medical Free Electron Laser Program contract FA9550-07-1-0101 (JGF). LB acknowledges support from NIH grant T32 DK 07760. DCA acknowledges support from the Natural Sciences and Engineering Research Council of Canada and the Heritage Scholarship Fund of the Province of Alberta. THT acknowledges support from the Taiwan Merit Scholarship from the National Science Council of Taiwan. The authors acknowledge the facility support from VA Boston Healthcare System and useful discussions with Dr. Qin Huang.

References

- Adler, D.C., Zhou, C., Tsai, T.-H., Schmitt, J., Huang, Q., Mashimo, H. *et al.* (2009) Three-dimensional endomicroscopy of the human colon using optical coherence tomography. *Optics Express* 17: 784–796.
- Adler, D.C., Chen, Y., Huber, R., Schmitt, J., Connolly, J. and Fujimoto, J.G. (2007)

Three-dimensional endomicroscopy using optical coherence tomography. *Nature Photon* 1: 709–716.

Barbatzas, C., Spencer, G.M., Thorpe, S.M., Sargeant, L.R. and Bown, S.G. (1996) Nd:YAG laser treatment for bleeding from radiation proctitis. *Endoscopy* 28: 497–500.

Baum, C.A., Biddle, W.L. and Miner Jr, P.B. (1989) Failure of 5-aminosalicylic acid enemas to improve chronic radiation proctitis. *Dig Dis Sci* 34: 758–760.

Bloomfield, R.S., Rockey, D.C. and Shetzline, M.A. (2001) Endoscopic therapy of acute diverticular hemorrhage. *Am J Gastroenterol* 96: 2367–2372.

Bouma, B.E., Tearney, G.J., Compton, C.C. and Nishioka, N.S. (2000) High-resolution imaging of the human esophagus and stomach *in vivo* using optical coherence tomography. *Gastrointest Endosc* 51: 467–474.

Chen, Y., Aguirre, A.D., Hsiung, P.-L., Huang, S.-W., Mashimo, H., Schmitt, J.M. *et al.* (2008) Effects of axial resolution improvement on optical coherence tomography imaging of gastrointestinal tissues. *Opt Exp* 16: 2469–2485.

Chen, Y., Aguirre, A.D., Hsiung, P.L., Desai, S., Herz, P.R., Pedrosa, M. *et al.* (2007) Ultrahigh resolution optical coherence tomography of Barrett's esophagus: preliminary descriptive clinical study correlating images with histology. *Endoscopy* 39: 599–605.

Chen, Z., Milner, T.E., Dave, D. and Nelson, J.S. (1997a) Optical Doppler tomographic imaging of fluid flow velocity in highly scattering media. *Optics Letters* 22: 64–66.

Chen, Z., Milner, T.E., Srinivas, S., Wang, X., Malekafzali, A., Van Gemert, M.J.C. *et al.* (1997b) Noninvasive imaging of *in vivo* blood flow velocity using optical Doppler tomography. *Opt Lett* 22: 1119–1121.

Counter, S.F., Froese, D.P. and Hart, M.J. (1999) Prospective evaluation of formalin therapy for radiation proctitis. *Am J Surg* 177: 396–398.

De Parades, V., Etienne, I., Bauer, P., Bourguignon, J., Meary, N., Mory, B. *et al.* (2005) Formalin application in the treatment of chronic radiation-induced hemorrhagic proctitis – an effective but not risk-free procedure: a prospective study of 33 patients. *Dis Colon Rectum* 48: 1535–1541.

Donaldson, S.S. (1994) Radiation proctitis after prostate carcinoma therapy. *JAMA* 271: 819–820.

Dunkin, B.J., Martinez, J., Bejarano, P.A., Smith, C.D., Chang, K., Livingstone, A.S. *et al.* (2006) Thin-layer ablation of human esophageal epithelium using a bipolar radiofrequency balloon device. *Surg Endosc Other Interv Tech* 20: 125–130.

Evans, J.A., Poneros, J.M., Bouma, B.E., Bressner, J., Halpern, E.F., Shishkov, M. *et al.* (2006) Optical coherence tomography to identify intramucosal

carcinoma and high-grade dysplasia in Barrett's esophagus. *Clin Gastroenterol Hepatol* 4: 38–43.

Fantin, A.C., Binek, J., Suter, W.R. and Meyenberger, C. (1999) Argon beam coagulation for treatment of symptomatic radiation-induced proctitis. *Gastrointest Endosc* 49: 515–518.

Ganz, R.A., Utley, D.S., Stern, R.A., Jackson, J., Batts, K.P. and Termin, P. (2004) Complete ablation of esophageal epithelium with a balloon-based bipolar electrode: a phased evaluation in the porcine and in the human esophagus. *Gastrointest Endosc* 60: 1002–1010.

Gilinsky, N.H., Burns, D.G., Barbezat, G.O., Levin, W., Myers, H.S. and Marks, I.N. (1983) The natural history of radiation-induced proctosigmoiditis: an analysis of 88 patients. *Q J Med* 52: 40–53.

Haboubi, N.Y., Schofield, P.F. and Rowland, P.L. (1988) The light and electron microscopic features of early and late phase radiation-induced proctitis. *Am J Gastroenterol* 83: 1140–1144.

Huang, D., Swanson, E.A., Lin, C.P., Schuman, J.S., Stinson, W.G., Chang, W. *et al.* (1991) Optical coherence tomography. *Science* 254: 1178–1181.

Hubbard, N. and Velanovich, V. (2007) Endoscopic endoluminal radiofrequency ablation of Barrett's esophagus in patients with funduplications. *Surg Endosc Other Intervent Tech* 21: 625–628.

Isenberg, G., Sivak, M.V., Chak, A., Wong, R.C.K., Willis, J.E., Wolf, B. *et al.* (2005) Accuracy of endoscopic optical coherence tomography in the detection of dysplasia in Barrett's esophagus: a prospective, double-blinded study. *Gastrointest Endosc* 62: 825–831.

Izatt, J.A., Kulkarni, M.D., Yazdanfar, S., Barton, J.K. and Welch, A.J. (1997) In vivo bidirectional color doppler flow imaging of picoliter blood volumes using optical coherence tomography. *Opt Lett* 22: 1439–1441.

Jäckle, S., Gladkova, N., Feldchtein, F., Terentjeva, A., Brand, B., Gelikonov, G. *et al.* (2000) In vivo endoscopic optical coherence tomography of the human gastrointestinal tract – toward optical biopsy. *Endoscopy* 32: 743–749.

Jensen, D.M., Machicado, G.A., Cheng, S., Jensen, M.E. and Jutabha, R. (1997) A randomized prospective study of endoscopic bipolar electrocoagulation and heater probe treatment of chronic rectal bleeding from radiation telangiectasia. *Gastrointest Endosc* 45: 20–25.

Kaassis, M., Oberti, F., Burtin, P. and Boyer, J. (2000) Argon plasma coagulation for the treatment of hemorrhagic radiation proctitis. *Endoscopy* 32: 673–676.

Kennedy, M., Bruninga, K., Mutlu, E.A., Losurdo, J., Choudhary, S. and Keshavarzian, A. (2001) Successful and sustained treatment of chronic radiation proctitis

with antioxidant vitamins E and C. *Am J Gastroenterol* 96: 1080–1084.

Kochhar, R., Patel, F., Dhar, A., Sharma, S.C., Ayyagari, S., Aggarwal, R. *et al.* (1991) Radiation-induced proctosigmoiditis. prospective, randomized, double-blind controlled trial of oral sulfasalazine plus rectal steroids versus rectal sucralfate. *Dig Dis Sci* 36: 103–107.

Li, X.D., Boppert, S.A., Van Dam, J., Mashimo, H., Mutinga, M., Drexler, W. *et al.* (2000) Optical coherence tomography: advanced technology for the endoscopic imaging of Barrett's esophagus. *Endoscopy* 32: 921–930.

Lucarotti, M.E., Mountford, R.A. and Bartolo, D.C. (1991) Surgical management of intestinal radiation injury. *Dis Colon Rectum* 34: 865–869.

Mashimo, H., Chen, Y., Huang, S.W., Huang, Q., Aguirre, A., Schmitt, J. *et al.* (2007) Endoscopic optical coherence tomography reveals Barrett's Underneath squamous neo-epithelium after radiofrequency ablation. *Gastroenterology* 132: A96.

Maunoury, V., Brunetaud, J.M. and Cortot, A. (1991) Bipolar electrocoagulation treatment for hemorrhagic radiation injury of the lower digestive tract. *Gastrointest Endosc* 37: 492–493.

Poneros, J.M., Brand, S., Bouma, B.E., Tearney, G.J., Compton, C.C. and Nishioka, N.S. (2001) Diagnosis of specialized intestinal metaplasia by optical coherence tomography. *Gastroenterology* 120: 7–12.

Qi, X., Sivak, M.V., Isenberg, G., Willis, J.E. and Rollins, A.M. (2006) Computer-aided diagnosis of dysplasia in Barrett's esophagus using endoscopic optical coherence tomography. *J Biomed Opt* 11: 10.

Ramirez, F.C., Johnson, D.A., Zierer, S.T., Walker, G.J. and Sanowski, R.A. (1996) Successful endoscopic hemostasis of bleeding colonic diverticula with epinephrine injection. *Gastrointest Endosc* 43: 167–170.

Rotondano, G., Bianco, M.A., Marmo, R., Piscopo, R. and Cipolletta, L. (2003) Long-term outcome of argon plasma coagulation therapy for bleeding caused by chronic radiation proctopathy. *Dig Liver Dis* 35: 806–810.

Sebastian, S., O'Connor, H., O'Morain, C. and Buckley, M. (2004) Argon plasma coagulation as first-line treatment for chronic radiation proctopathy. *J Gastroenterol Hepatol* 19: 1169–1173.

Sharma, V.K., Kim, H.J., Das, A., Dean, P., Depetris, G. and Fleischer, D.E. (2008) A prospective pilot trial of ablation of Barrett's esophagus with low-grade dysplasia using stepwise circumferential and focal ablation (Halo system). *Endoscopy* 40: 380–387.

Sharma, V.K., Wang, K.K., Overholt, B.F., Lightdale, C.J., Fennerty, M.B., Dean, P.J. *et al.* (2007) Balloon-based, circumferential, endoscopic radiofrequency ablation of Barrett's esophagus: 1-year

follow-up of 100 patients. *Gastrointest Endosc* 65: 185–195.

Sivak Jr, M.V., Kobayashi, K., Izatt, J.A., Rollins, A.M., Ung-Runyawee, R., Chak, A. *et al.* (2000) High-resolution endoscopic imaging of the GI tract using optical coherence tomography. *Gastrointest Endosc* 51: 474–479.

Smith, C.D., Bejarano, P.A., Melvin, W.S., Patti, M.G., Muthusamy, R. and Dunkin, B.J. (2007) Endoscopic ablation of intestinal metaplasia containing high-grade dysplasia in esophagectomy patients using a balloon-based ablation system. *Surg Endosc Other Intervent Techn* 21: 560–569.

Taieb, S., Rolachon, A., Cenni, J.C., Nancey, S., Bonvoisin, S., Descos, L. *et al.* (2001) Effective use of argon plasma coagulation in the treatment of severe radiation proctitis. *Dis Colon Rectum* 44: 1766–1771.

Talley, N.A., Chen, F., King, D., Jones, M. and Talley, N.J. (1997) Short-chain fatty acids in the treatment of radiation proctitis: a randomized, double-blind, placebo-controlled, cross-over pilot trial. *Dis Colon Rectum* 40: 1046–1050.

Taylor, J.G., Disario, J.A. and Bjorkman, D.J. (2000) KTP laser therapy for bleeding from chronic radiation proctopathy. *Gastrointest Endosc* 52: 353–357.

Taylor, J.G., Disario, J.A. and Buchi, K.N. (1993) Argon-laser therapy for hemorrhagic radiation proctitis – long-term results. *Gastrointest Endosc* 39: 641–644.

Tearney, G.J., Brezinski, M.E., Bouma, B.E., Boppart, S.A., Pitvis, C., Southern, J.F. *et al.* (1997) In vivo endoscopic optical biopsy with optical coherence tomography. *Science* 276: 2037–2039.

Tjandra, J.J. and Sengupta, S. (2001) Argon plasma coagulation is an effective treatment for refractory hemorrhagic radiation proctitis. *Dis Colon Rectum* 44: 1759–1765; discussion 1771.

Ventrucci, M., Di Simone, M.P., Giulietti, P. and De Luca, G. (2001) Efficacy and safety of Nd:YAG laser for the treatment of bleeding from radiation proctocolitis. *Dig Liver Dis* 33: 230–233.

Viggiano, T.R., Zigelboim, J., Ahlquist, D.A., Gostout, C.J., Wang, K.K. and Larson, M.V. (1993) Endoscopic Nd-YAG laser coagulation of bleeding from radiation proctopathy. *Gastrointest Endosc* 39: 513–517.

Villavicencio, R.T., Rex, D.K. and Rahmani, E. (2002) Efficacy and complications of argon plasma coagulation for hematochezia related to radiation proctopathy. *Gastrointest Endosc* 55: 70–74.

Visit SAGE journals online
<http://tag.sagepub.com>

 SAGE JOURNALS
Online